IMAGES in PAEDIATRIC CARDIOLOGY

Brief Images **Zrinzo S,* Grech V.** Brief Images: Cerebral arteriovenous malformation. Images Paediatr Cardiol 2002;13:22-26**

* ***Consultant, Department of Radiology***

** ***Editor-in-Chief, Images Paediatr Cardiol***

MeSH

Cerebral arteriovenous malformation

Cerebral arteriovenous malformations (AVM) are defined as lesions of the vasculature wherein blood bypasses the capillary system, flowing from arteries directly into veins. These lesions are congenital in nature and are caused by failure of differenciation of the embryonic vascular plexus. This direct connection exposes the low resistance venous system to abnormally pressures leading to the formation of enlarged feeding vessels, the lesion itself and enlarged venous draining vessels. Such lesions may therefore continue to enlarge postnatally.[1]

Presentation in the paediatric age group may be with heart failure, macrocephaly, frank hydrocephalus , benign intracranial hypertension or prominent scalp veins. In older individuals, presentation may be with haemorrhage (acute headache or neurological deficit), fits, chronic headaches or chronic and progressive neurological deficit/s due to mass effect and/or ischaemia of the surrounding brain due to steal.[2]

This cranial ultrasound is of an infant from a developing country, the product of a first cousin marriage, and who also, incidentally, had presented to a tertiary cardiology centre with scimitar syndrome.

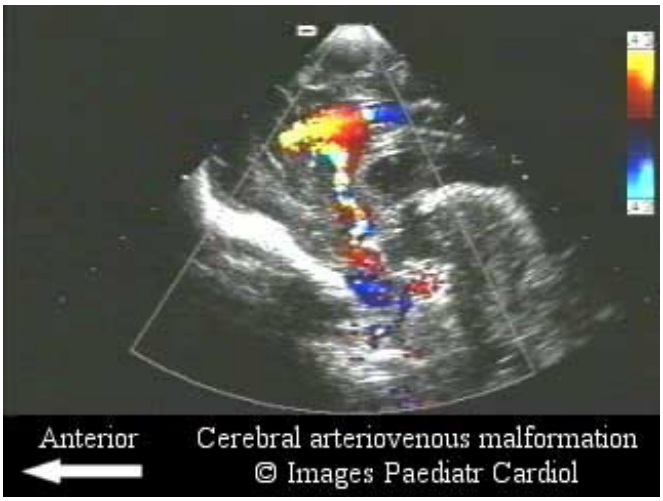

Figure 1: AVM arising from carotid artery

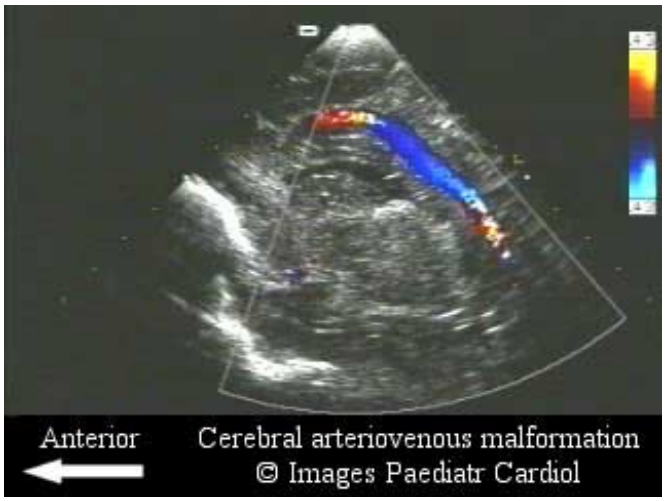

Figure 2: Draining vein to the inferior sagittal sinus

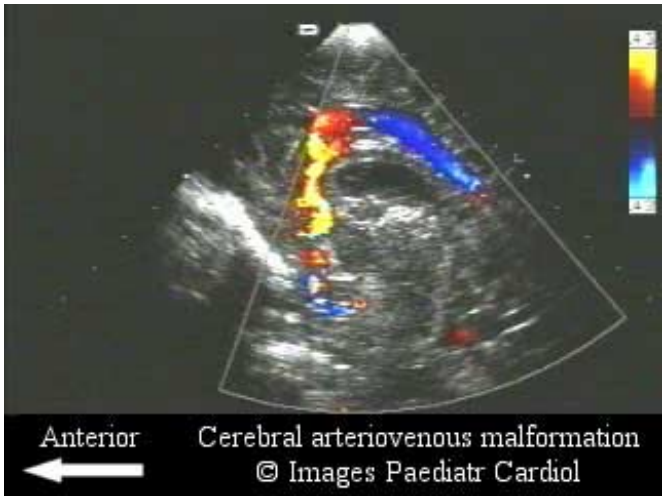

Figure 3: Arterial and venous phases of AVM

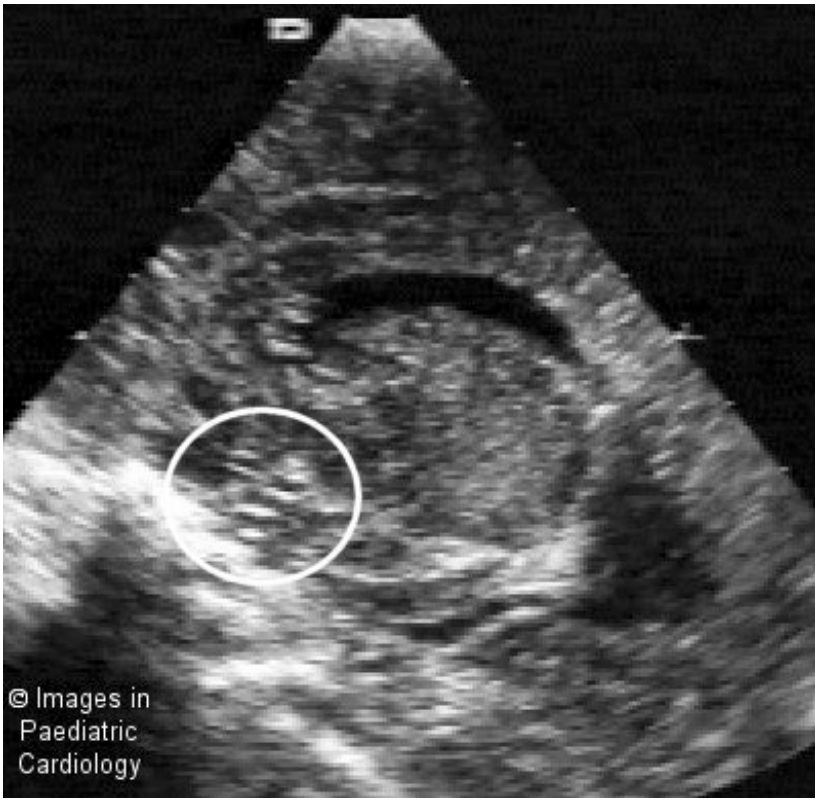

Figure 4: AVM (circled)

Figure 5: Pulse wave Doppler showing arterial envelope in ascending portion of AVM

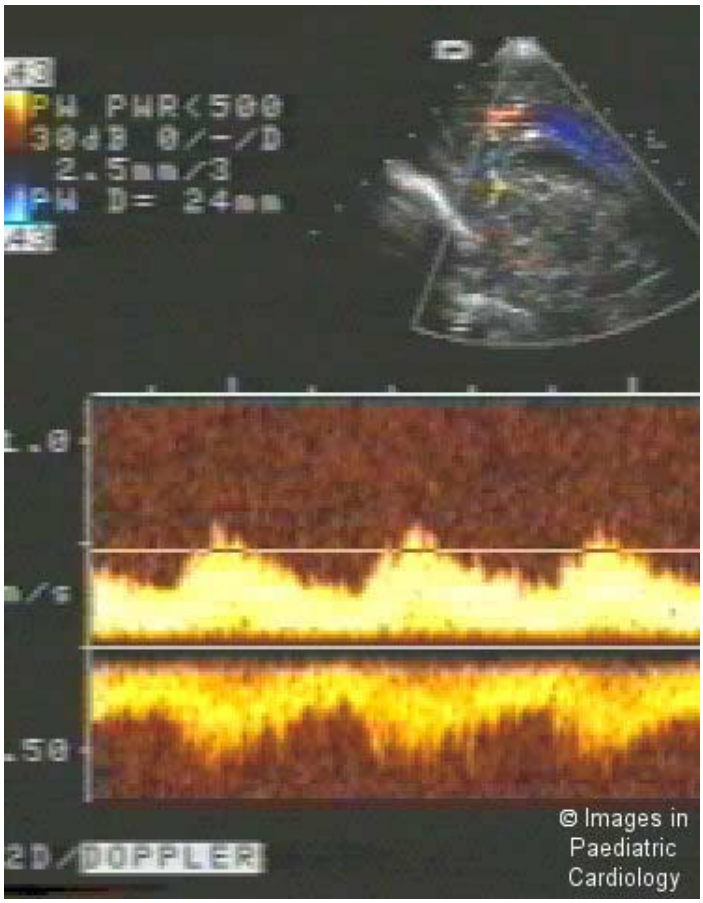

Figure 6: Pulse wave Doppler at junction of venous drainage of AVM

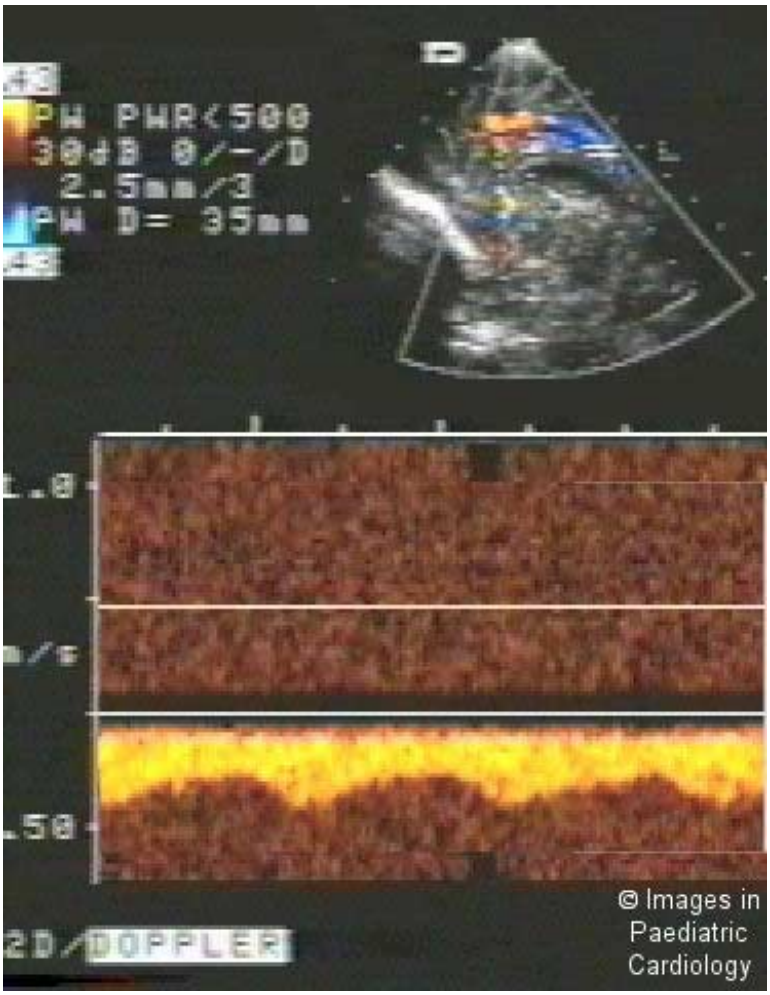

Figure 7: Pulse wave Doppler showing venous envelope in descending portion of AVM

Further imaging may be obtained by magnetic resonance imaging and angiography.

Treatment may be surgical; or by stereotactic radiosurgery; or by neurointerventional radiology with ischaemic obliteration of vessels with glues, particles or coils; or by any combination of the above.[3] Angiography is particularly useful for grading lesions with regard to likelihood of success with surgical intervention.[4]

References

1. McCormick WF: The pathology of vascular ("arteriovenous") malformations. J Neurosurg 1966;24:807-816.
2. Ondra SL, Troupp H, George ED, Schwab K: The natural history of symptomatic arteriovenous malformations of the brain: a 24-year follow-up assessment. J Neurosurg 1990;73:387-391.
3. Fleetwood IG, Steinberg GK. Arteriovenous malformations. Lancet 2002;359:863-73
4. Spetzler RF, Martin NA: A proposed grading system for arteriovenous malformations. J Neurosurg 1986;65: 476-83.

Contact information

Dr. Salvina.Zrinzo
Consultant Radiologist
St. Luke's Hospital
Guardmangia MSD09
Malta
salvina.zrinzo@gov.mt

© Images in
Paediatric Cardiology
1999-2003